

# Dentition in Dogs

## INTRODUCTION TO PUPPY TEETH:

Rottweiler puppies should have 28 temporary teeth that erupt at about three to four weeks of age. They will eventually have 42 permanent adult teeth that begin to emerge at about three to four months of age. As puppies, there are 14 upper and 14 lower puppy teeth.

There are four types of teeth with different functions:

**Incisors:** Used for cutting and nibbling food. Incisors are the front teeth situated directly in-between the canines. In adults and puppies, there are six upper and six lower. These are the front teeth and all six upper and all six lower are all in a row. The center two teeth are usually somewhat smaller and the incisor teeth get larger as you move out and away from the center.

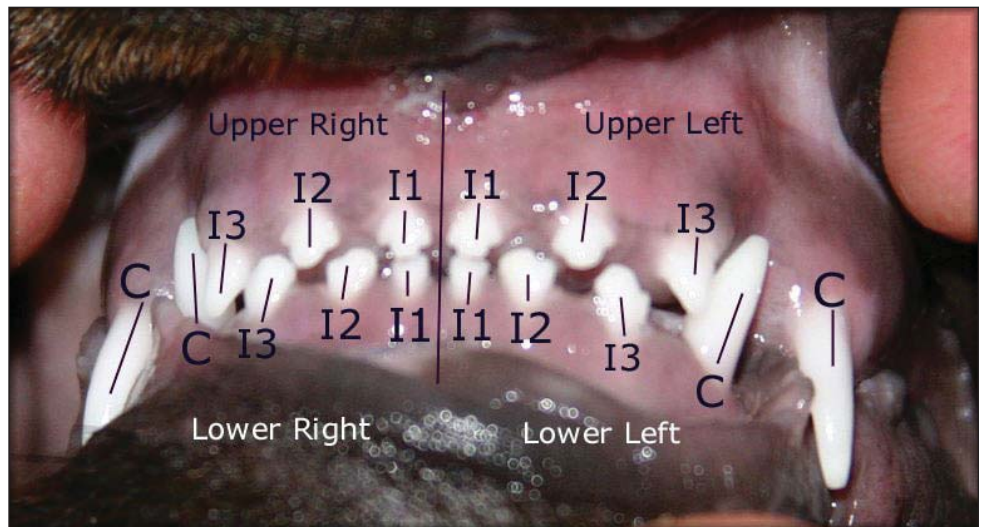
**Canine teeth:** Used to hold and tear food. The canines are the large fangs. The lower canines lock in position in front of the upper canines. The canines are situated directly between the incisors and the premolars. In adults and puppies, there are exactly two upper and two lower canines. There is one on each side of the upper jaw and one on each side of the lower jaw.

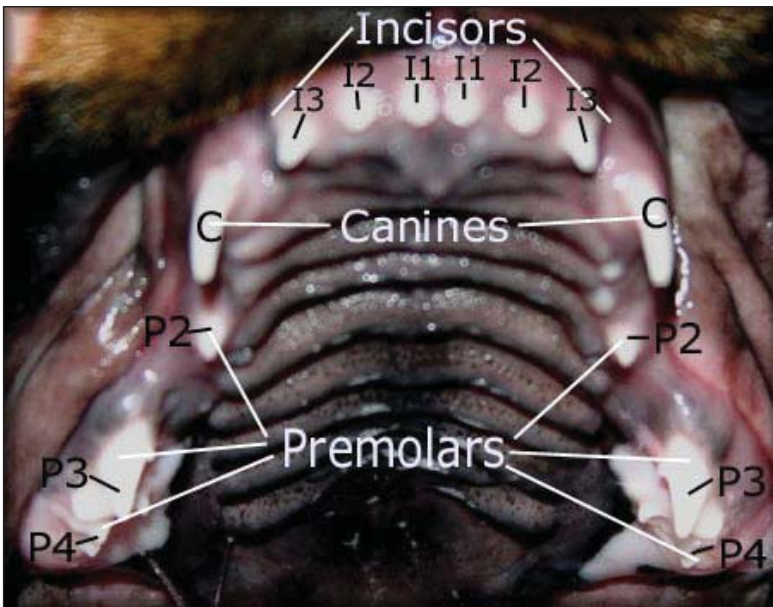
**Premolars:** Used for cutting, holding, and shearing food. The premolars are positioned behind the canines and in front of the molars. Puppies do not have all of their premolars, but when the adult teeth come in, there will be 8 premolars on the top and 8 premolars on the bottom. Four premolars are on each side of the upper jaw and four premolars are on each side of the lower jaw in adults.

**Molars:** Used to grind food. The molars are positioned behind the premolars and are the last teeth in the back of the jaw. There are 4 molars on the top, two on each side, and 6 molars on the bottom, three on each side. Puppies don't have molars.

### Diagram #1: Nine week old puppy, showing a correct scissors bite.

In Diagram #1, you can see the incisors labeled "I", 1,2,& 3. Each tooth is identified by the upper or lower jaw and distinguished between left and right sides. The teeth labeled "C" are the canines. The large gaps between the teeth on even this nine week old puppy are normal and the gaps get larger as the puppy grows, prior to the adult teeth coming in. These puppy teeth are extremely tiny and it's not hard to tell the difference between them and adult teeth.



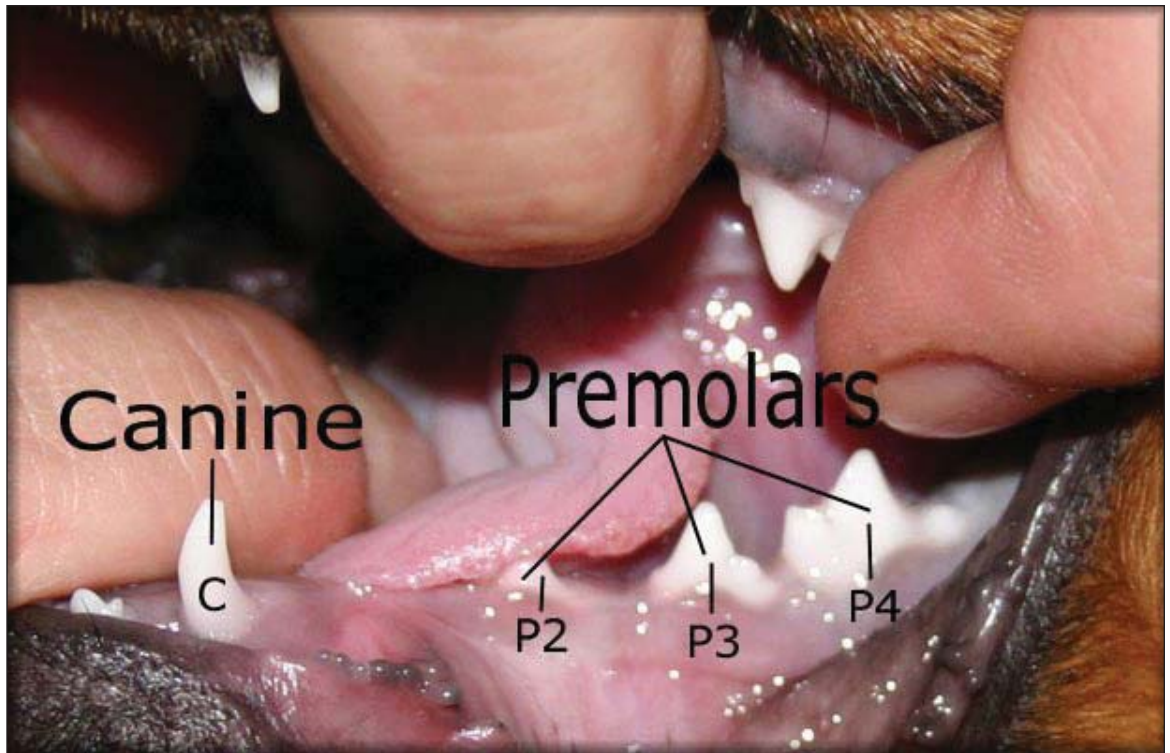


**Diagram #2: Upper teeth of nine week old puppy, showing 14 teeth.**

Diagram #2 shows what you can expect to see in your own puppy's mouth. There are large gaps between the teeth at this point which should not be cause for alarm, yet. If you see gaps like this in an adult's mouth, you probably have missing teeth. In diagram #2, if you count the three back teeth you can see on each side, the Premolars, that's six, then add the two Canines, that's eight, and then add the six Incisors, that's a total of 14 teeth on the top.

**Diagram #3: Lower teeth of nine week old puppy.**

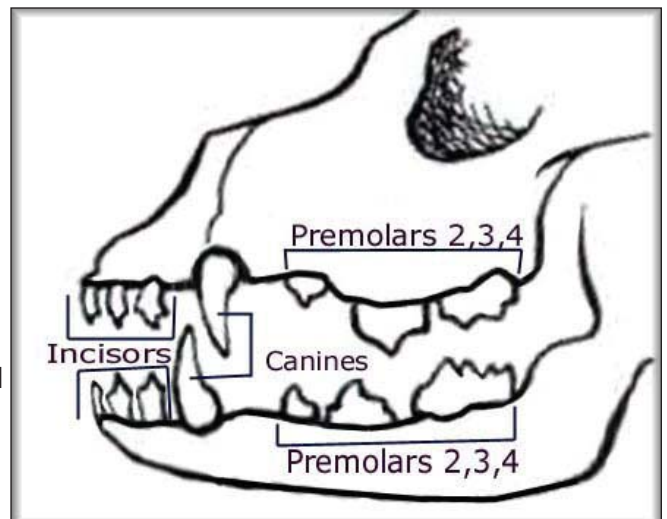
In Diagram #3, you see half of the lower jaw. It's nearly impossible to take a photo of the entire lower jaw showing all the lower teeth at the same time because the tongue and the lips naturally cover the teeth. The P1's and P2's are the hardest of all the teeth to show. Puppies don't have P1's, so there aren't any in Diagram #3.



The P1's will be coming up in the gap you see in Diagram #3 in-between the teeth that are labeled "Canine" and "P2". In Diagram #3, if you count the three back teeth you can see, the Premolars, add the ones on the other side, that's six, add the two canines, that's eight, and finally add the six incisors, that's 14 on the bottom.

**Diagram #4: Chart showing a full set of puppy teeth.**

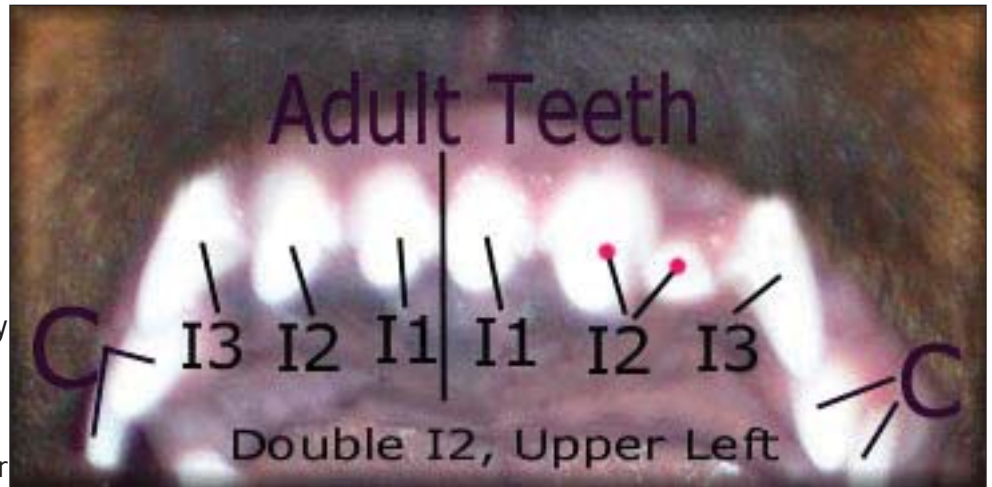Puppies should lose a puppy tooth before the corresponding adult tooth emerges, but many times with Rottweilers, you'll see both the puppy tooth and the adult tooth side by side. This is especially true of the canines (commonly called the fangs). If a puppy tooth is still in place when an adult tooth



begins to show, and it shows no signs of looseness, see your veterinarian to decide if the puppy tooth needs to be pulled so the dog's occlusion is not affected.

**Diagram #5: Upper teeth of a youth dog under 9 months old, showing extra teeth.**

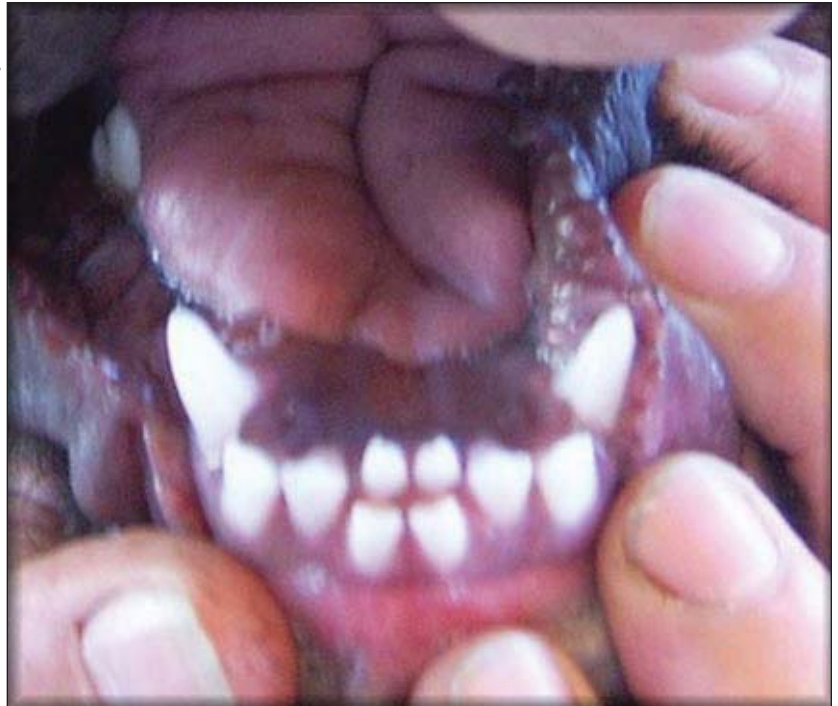In Diagram #5, this photo actually shows newly erupted adult teeth still in transition, and one extra incisor tooth. The canines are marked with "C", and at this point the puppy canines are side by side with the adult canines which are still coming in. All of the large teeth in-between the canines are adult incisors. See how much larger



the adult teeth are, and the gaps are closed. I'm pointing out the difference in size, because people get confused when they see an extra adult tooth. They think that it must be a puppy tooth that has not fallen out, but visually, you can see that the difference in size is enormous. Thus, any additional teeth in the mouth of this dog are extra adult teeth, and a decision must be made carefully and quickly as to whether or not the extra teeth should be pulled. Extra teeth left in the mouth, especially incisors, can throw a bite off and render the dog as pet quality and show disqualified.

**Diagram #6: Lower teeth of a youth dog under 9 months old, showing extra teeth.**

In Diagram #6, this photo shows newly erupted adult teeth still in transition, and two extra adult incisor teeth on the bottom which have pushed the bottom incisors forward and out of alignment for a scissors bite. It is vitally important to keep a close eye on your puppy's teeth watching for abnormalities.



## INTRODUCTION TO ADULT TEETH:

Rottweiler adults should have 42 permanent teeth in number, 20 upper and 22 lower. The teeth should be strong, correctly placed, and meeting in a scissors bite. The lower incisors should touch the inside of the upper incisors.

The adult canine teeth of Rottweilers are essential to be allowed to show and breed. The AKC Rottweiler Standard currently allows one missing tooth. The FCI Standard, which is what all the rest of the world besides America goes by, doesn't allow any missing teeth for the Rottweiler breed in order to be considered show and breeding quality. Don't make the mistake of walking into a show ring without counting your dog's teeth and checking your dog's bite first.

### FCI Standard:

Jaws / Teeth:

Upper and lower jaw strong and broad. Strong complete dentition (42 teeth) with scissor bite, the upper incisors closely overlapping the lower incisors.

Faults:

Jaws: Narrow lower jaw.

Bite: Pincher bite.

Eliminating Faults:

Teeth:

Overshot or undershot bite, wry mouth; lack of one incisive tooth, one canine, one premolar and one molar.

### AKC Standard:

Bite and Dentition--Teeth 42 in number (20 upper, 22 lower), strong, correctly placed, meeting in a scissors bite--lower incisors touching inside of upper incisors.

Serious Faults--Level bite; any missing tooth.

Disqualifications--Overshot, undershot (when incisors do not touch or mesh); wry mouth; two or more missing teeth.

### Diagram #7:

Shows a correct scissors bite on an adult Rottweiler.

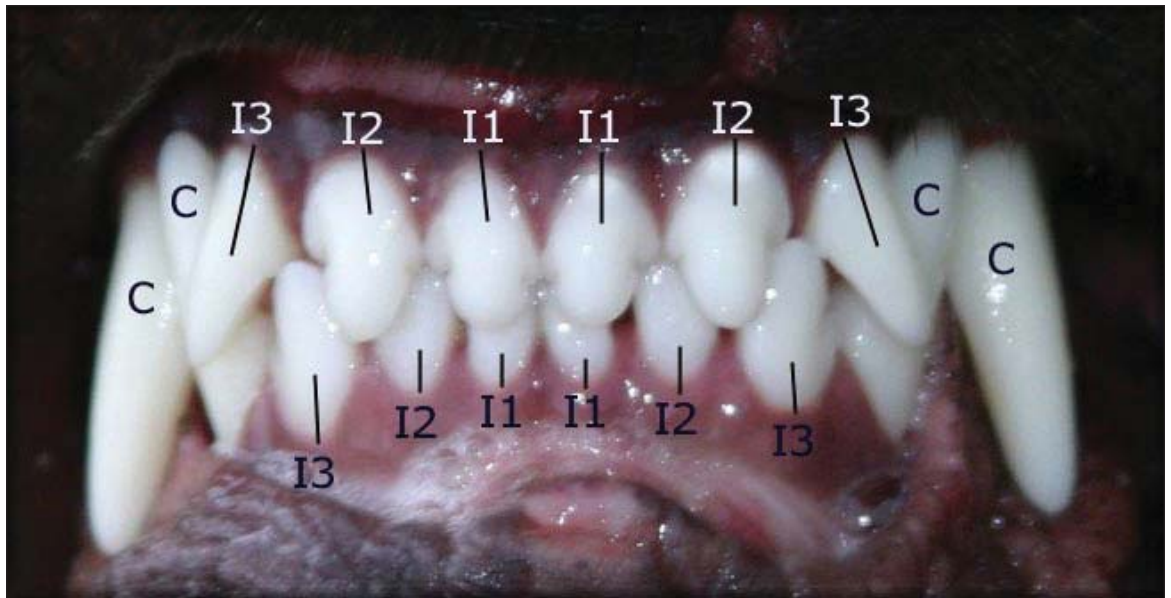


Diagram #8: Chart showing the correct number and placement of the upper and lower teeth.

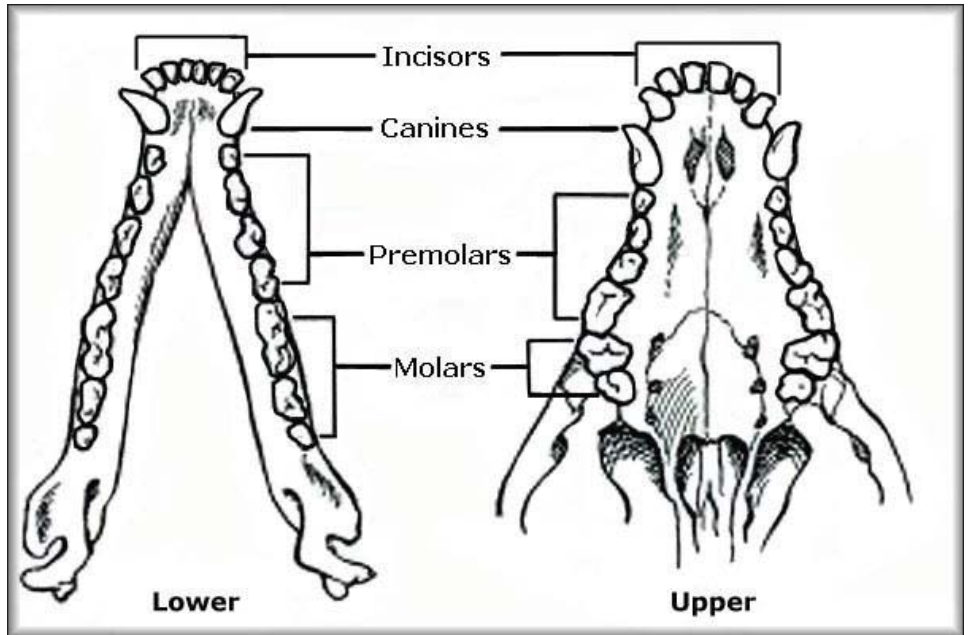


Diagram #9: Showing the jaw closed and how the teeth should mesh properly.

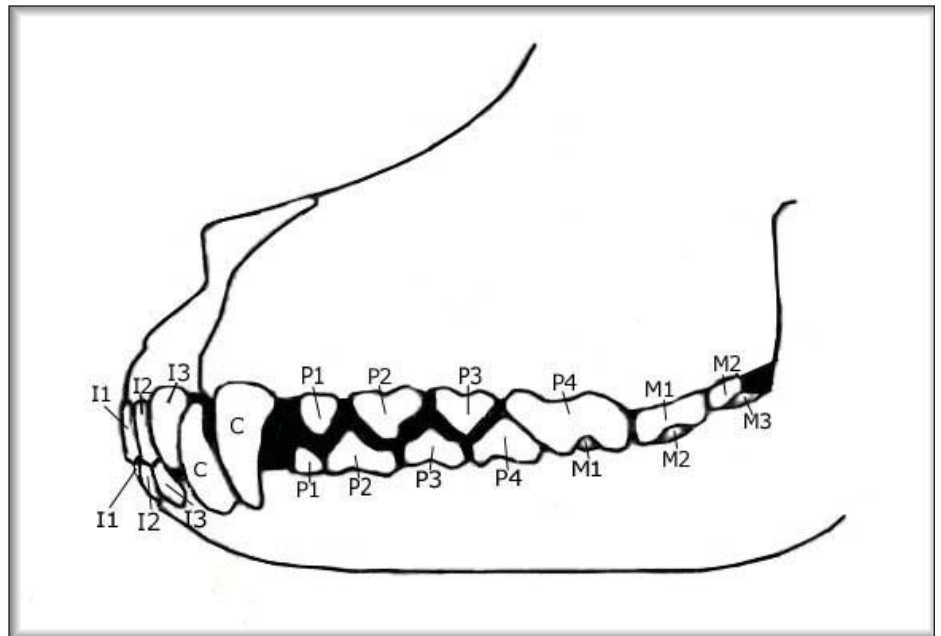
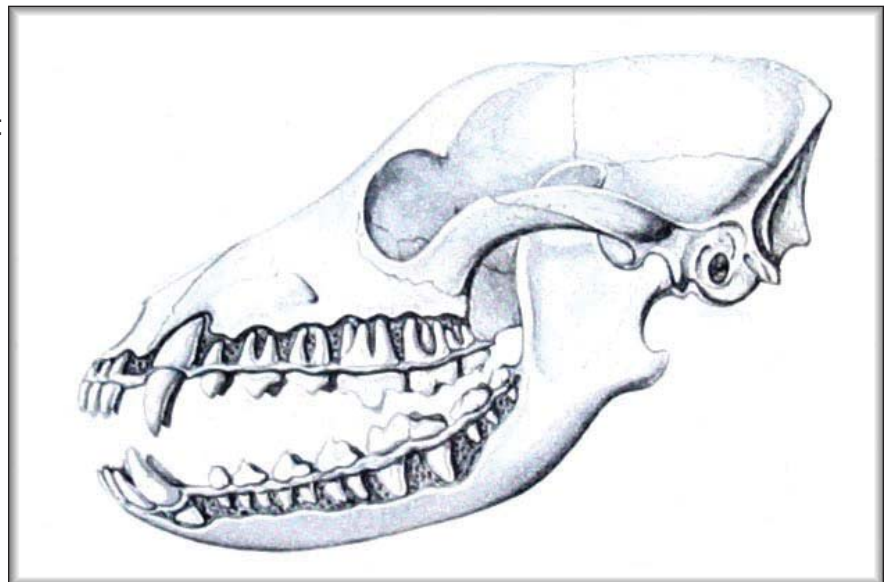
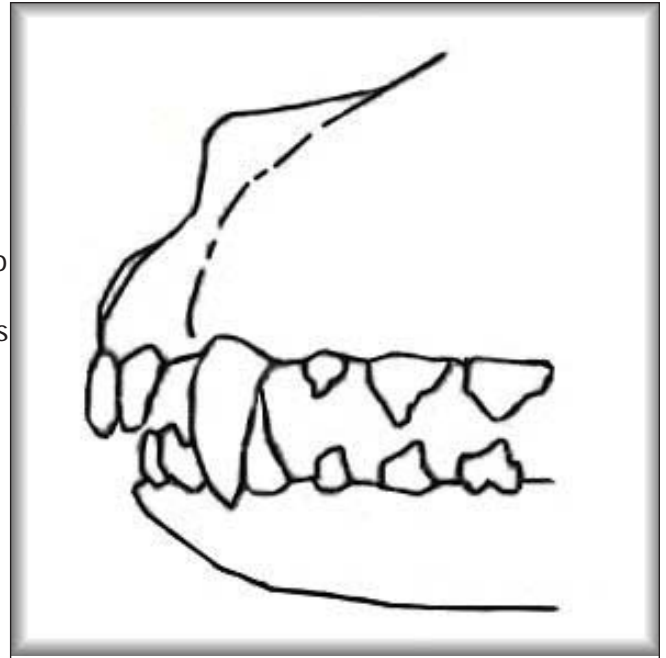


Diagram #10: A good view of the root system for the teeth.



**Diagram #11: View of a moderate overbite, with the canines in reverse order.**

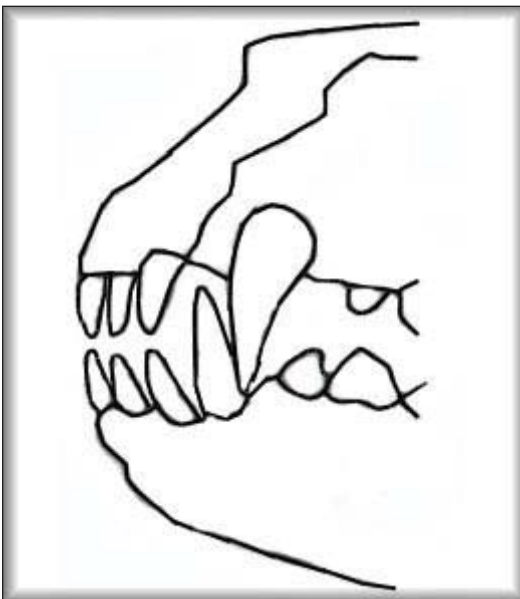
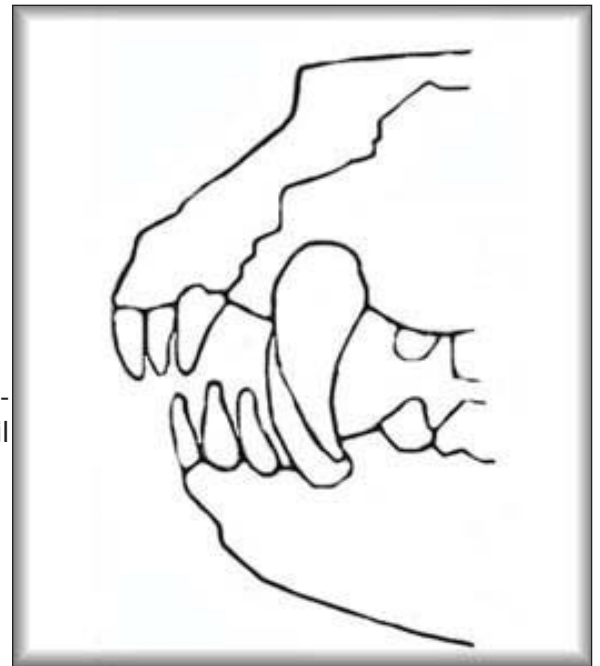
In Diagram #11, this drawing of a moderate overbite clearly shows that the lower canines will not mesh with the upper canines, and will in fact bore unnatural holes in the roof of the mouth of the dog. On overbites, the teeth find a place to go and do not interfere with the dog's ability to eat and certainly do not affect the health of the dog. Many veterinarians will tell people who have overbite puppies that they need to bring them in for surgical removal of the lower puppy canines because they are boring unnatural holes in the roof of the mouth. In all the time we've been breeding Rottweilers, overbites are the most common feature that occur rendering a puppy as pet quality. Of all of the overbite pet quality puppies we've produced, not one single one ever required any medical intervention or pulling of teeth because of the overbite and many times overbites do correct during the transition from puppy to adult.



**Diagram #12: Shows a regular overbite, a show disqualifying feature.**

In Diagram #12, the drawing shows a regular overbite. On occasion, a regular overbite can and sometimes does correct into a scissors bite.

A puppy's bottom jaw will continue to grow until they are approximately nine months old, which means the bite is in transition until 9 to 11 months old. It should be noted that the top jaw is also in transition and growing during this period. The bite can go either way, from scissors to underbite or from scissors to overbite, or the most common would be from scissors to level bite.

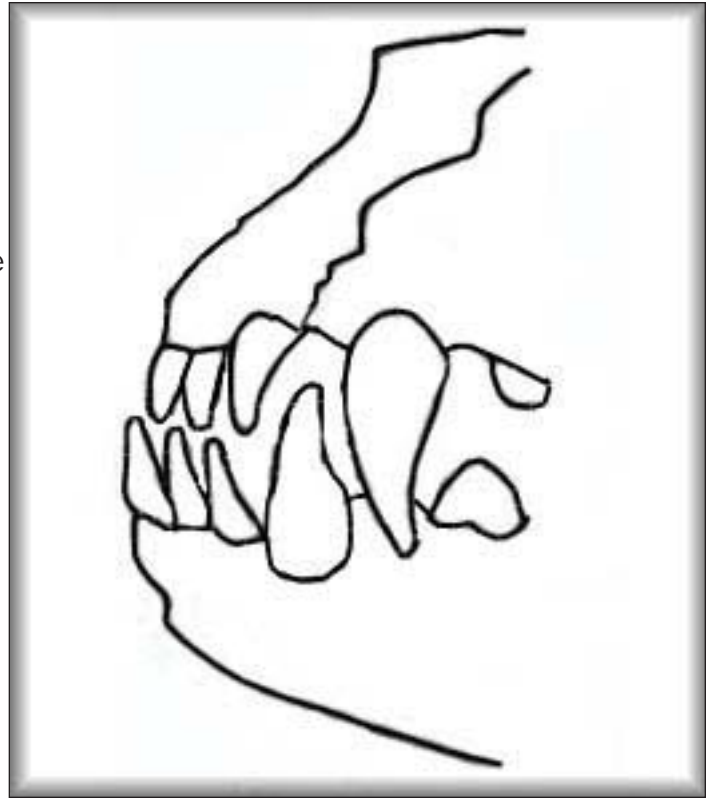


**Diagram #13: Shows a level bite.**

In Diagram #13, the drawing shows a level bite which is breedable and showable and is not a disqualifying fault in the show ring, but it is a fault. A level bite is often heavily penalized by judges and is not desirable. Many older Rottweilers have level bites that show up later in life. Sometimes these bites are caused from excessive chewing or excessive tugging on the jaw.

**Diagram #14: Shows an underbite, a show disqualifying feature.**

In Diagram #14, the drawing shows an underbite which is much less common than the overbite and level bite. In all the years we've been in Rottweilers, an underbite has never corrected to a scissors bite. While it is possible that it could happen, the odds against it are astronomical.



The only bite abnormality we don't currently have a drawing or photo of is the wry bite. A wry bite is when the teeth are crooked. Some of the teeth would be considered an overbite and some would be considered an underbite and some meet dead level. I've only seen a handful of wry bites, and some were caused by outside influences, and some were purely genetic.

If your dog's teeth become broken, a canine dentist can prepare a metal or porcelain crown. A broken tooth is a common problem, especially among outdoor dogs. Aggressive chewing on hard objects, such as rocks, cyclone fencing, cow hooves, bones or igloos, is a primary cause, and chewing on hard objects can also change a scissors bite to a bad bite and this would not be considered a genetic cause. Rottweilers are very aggressive chewers and their bites should be checked often and if you notice the teeth are shifting, you should remove any objects the dogs are chewing on. Rottweilers also can lose a tooth by pulling on cyclone fencing and crate doors and grating. Rottweilers have also been known to lose teeth from doing bite work and teeth have been pulled out of alignment from tug-of-war games.

Studies show that by age three, 80 percent of dogs exhibit signs of gum disease. Symptoms include yellow and brown build-up of tartar along the gum line, red inflamed gums and persistent bad breath. Small dog breeds are more likely to develop periodontal disease than large dogs because the teeth of small dogs are often too large for their mouths, according to veterinary dentistry experts. Plaque on dog's teeth are a concern because it can lead to heart disease. We highly recommend that you keep your dog's teeth clean by offering raw beef femur bones on a regular basis. We offer them regularly and let the dogs chew on them only long enough to clean their teeth, and then the bones are removed so that they don't chew all the enamel off their teeth. Sometimes only a half hour of chewing is sufficient to clean all the plaque off. Some dogs require a longer period of time.